The Incidence of posterior overhang of total knee implant and its effect on aseptic loosening

Jun Bae Kim M.D., Yong Lae Kim M.D., Tae Han Kim M.D.,
Yoon Whan Roh M.D., Suk Joo Lyu M.D., Hyung Wook Kang M.D.

Department of Orthopaedic Surgery, Seoul NOW Hospital

Introduction

Recently, there were several clinical reports of *early aseptic loosening after TKA with high flexion design* such as NexGen LPS-flex prosthesis.[1-3] Han et al [2, 3] reported that the occurrence of loosening was closely related to the maximal flexion angle achieved after TKA. To address this clinical finding, Zelle et al [4] tried to prove this in computational experimental study.
They showed that *tensile and shear stress concentrations at the implant-cement interface beneath the proximal part of the anterior flange increased during deep knee flexion* and concluded that femoral implant-cement interface is most likely to fail beneath the anterior flange during deep flexion. In addition, Choi et al [1] showed that protrusion (overhang) of the femoral component over posterior condyle of the distal femur were more prominent in the loosened group. We hypothesized that if there would be an *overhang of TKA implant over the* posterior femoral condyle, this may have an additional negative effect on loosening because the overhanged part of metal implant will have a leverage effect.
To address this issue, we investigated how often the posterior overhang of TKA implant happen in Korean population and assessed its effect on the femoral loosening with a review of literature.

Materials and Methods

To assess how often the posterior overhang happen, we measured the length of posterior condyle cut surface in 300 knees during TKA surgery (Fig.1) and compared these measurements with those of TKA implant of corresponding size (Fig.2) And to evaluate how these posterior overhang of TKA implant affect the loosening of implant, we reviewed related literature and tried to figure out the mechanism.

Fig. 1

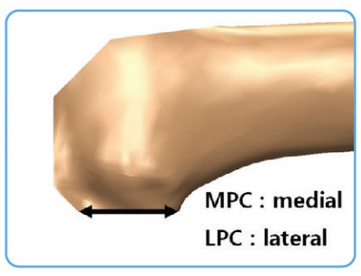

Fig. 2

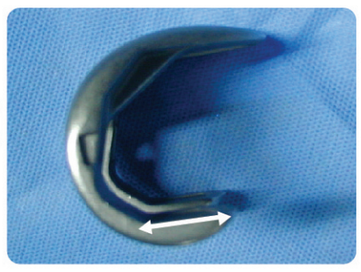

Results

Because of the diversity of the morphology of distal femur, even though the dimension of posterior condyle of TKA implant was located at the mean value of the measured patients data, the posterior overhang(Fig.5) of TKA implant was observed in 37.3% (medial) and 51.2%(lateral)(Fig. 3,4).

Fig. 3

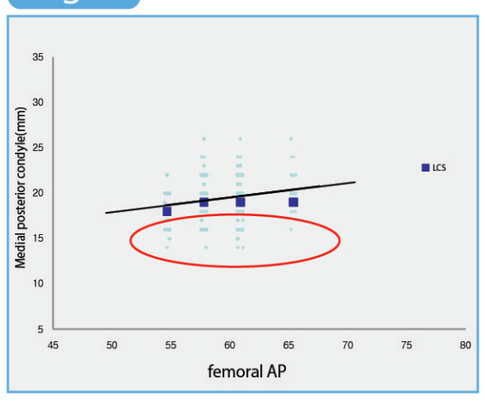

Fig. 4

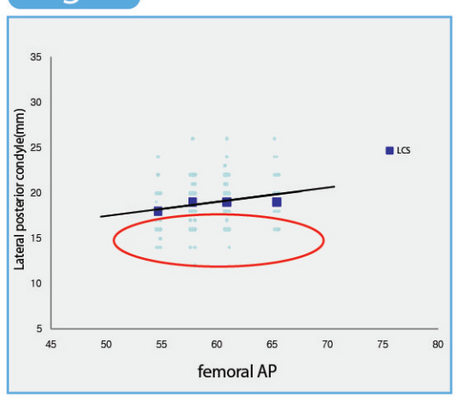

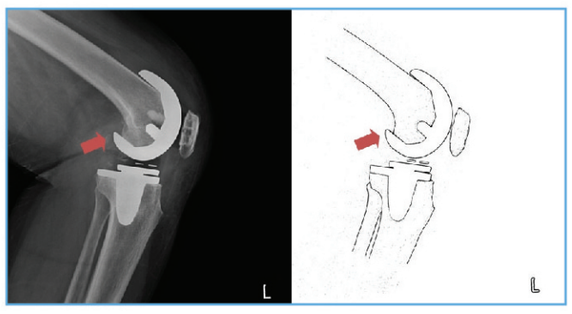

Fig. 5

Postoperative radiograph shows prominent overhang of implant at posterior condyle of femur.

We estimated the debonding force at implant-cement interface using the formula which Zelle et al [4] presented(Fig.6). In case posterior overhang occurred, as the overhanged part of metal implant will have a leverage effect and eventually increase tensile force at the implant-cement interface beneath the proximal part of the anterior flange, a patient who has posterior overhang and simultaneously can achieve deep flexion will have higher debonding force at anterior area and may have higher possibility of femoral loosening in the long term(Fig.7).

Fig. 6

Zeller et al[4] used Modified Hoffman failure criterion to determine whether a local interface stress state would lead to static interface debonding at anterior,posterior, and distal interface regions of interest.

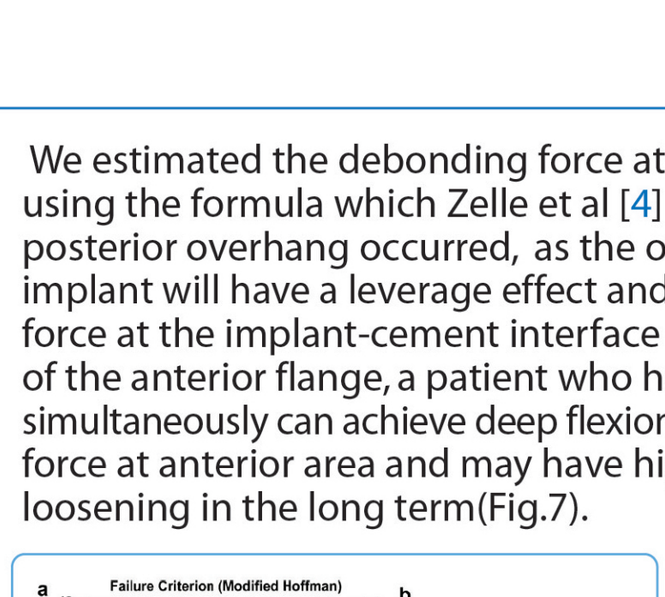

Fig. 7

Posterior overhang of implant will have a leverage effect to increase the tensile force at anterior surface. Eventually this can initiate debonding at this area and can increase risk of femoral loosening.

Discussion & Conclusion

The posterior overhang of TKA implant was observed to happen not uncommonly. As this overhang can promote the loosening of TKA implant theoretically, more attention to posterior implant overhang should be paid especially in the Korean population who are able to achieve deep knee bend after TKA. These findings also have several clinical meaning as follows;

1. If posterior overhang of implant is observed on postoperative radiograph, activities which will require deep knee bend such as squatting, kneeling and cross-leg sitting should not be encouraged to the patients even if they can do that.
2. During the surgery, undesirable action such as too much distal femur cutting, posterior cutting angled to anterior and over- removal of posterior osteophyte should be avoided, as these will increase posterior implant overhang.

References

1. Choi, Y.-J., et al., *Early Aseptic Loosening after Total Knee Replacement Using Legacy Posterior Stabilized-Flex Prosthesis.* Journal of the Korean Orthopaedic Association, 2012. 47(1): p. 35.
2. Han, H., S.B. Kang, and K. Yoon, *High incidence of loosening of the femoral component in legacy posterior stabilised-flex total knee replacement.* Journal of Bone & Joint Surgery, British Volume, 2007. 89(11): p. 1457-1461.
3. Han, H.S. and S.B. Kang, *Brief Followup Report: Does High-flexion Total Knee Arthroplasty Allow Deep Flexion Safely in Asian Patients?* Clin Orthop Relat Res, 2012.
4. Zelle, J., et al., *Does high-flexion total knee arthroplasty promote early loosening of the femoral component?* J Orthop Res, 2011. 29(7): p. 976-83.

서울나우병원